


Supplement to

Advanced OCULAR CARE

September 2010

Clinical Pearls and the Latest Evidence for Corticosteroid Use in Cataract and Anterior Segment Surgery



Including clinical experience with
difluprednate 0.05% emulsion.

Featuring:

Richard L. Lindstrom, MD	Paul Karpecki, OD
Carlos Buznego, MD	Robert H. Osher, MD
Eric D. Donnenfeld, MD	Michael B. Raizman, MD
Edward J. Holland, MD	Steven M. Silverstein, MD

Jointly sponsored by the Dulaney Foundation and Advanced Ocular Care.

Release date: September 2010. Expiration date: September 2011.

This continuing medical education activity is supported by an unrestricted educational grant from Alcon Laboratories, Inc.

STATEMENT OF NEED

In the anterior segment surgical setting, clinicians pay careful attention to the importance of managing inflammation and the risk of macula edema. Physicians must also negotiate the advantages and disadvantages associated with various steroid preparations (emulsions versus suspensions), whether or not the products contain the preservative benzalkonium chloride, how the agents are delivered, and how often they must be dosed. Continuing evolution of perioperative therapeutic plans using evidence-based clinical decision making skills is a vital aspect of providing patients with the safest approach to surgical vision improvement, the treatment of edema and uveitis, and the prevention of complications.¹⁻⁴

As the landscape of available therapeutic options expands, ophthalmologists need to consider expert opinions regarding changes to therapeutic practice patterns that may be necessary in order to provide high levels of patient care. The creation of effective surgical therapeutic plans involving many agents used perioperatively, including steroids, has a direct impact on patient safety and visual outcomes.⁵

As cataract patients increase by 60% in the next 15 years, surgeons will be under even more pressure to determine safe and effective surgical prophylaxis strategies to prevent unwanted adverse effects and improve outcomes.⁶

Appropriate dosing schedules, administration methods, perioperative approaches, incision techniques, and outcomes monitoring are critical to improving the safety of the most widely performed elective surgical procedures in ophthalmology.⁷⁻¹⁰ This CME activity will provide evidence-based knowledge with experts addressing the critical decisions required of surgeons during pharmaceutical strategy development for anterior segment procedures.

10. Donnenfeld ED, Kim T, Holland EJ, et al; American Society of Cataract and Refractive Surgery Cornea Clinical Committee. ASCRS White Paper: Management of infectious keratitis following laser in situ keratomileusis. *J Cataract Refract Surg*. 2005;31(10):2008-2011.

TARGET AUDIENCE

This certified CME activity is designed for general ophthalmologists and anterior segment surgeons specializing in cornea, refractive, and cataract surgery.

LEARNING OBJECTIVES

Upon completion of this activity, the participant should be able to:

- discuss the most current clinical trials involving ophthalmic steroid dosing and visual function outcomes in cataract surgery
- describe the impact of current methods to treat refractory macular edema
- describe the dose uniformity among various preparations of steroids
- understand the most current dosing methods for uveitis using topical and injection delivery

METHOD OF INSTRUCTION

Participants should read the continuing medical education (CME) activity in its entirety. After reviewing the material, please complete the self-assessment test, which consists of a series of multiple-choice questions. To answer these questions online and receive real-time results, please visit <http://www.dulaneyfoundation.org> and click "Online Courses."

Upon completing the activity and achieving a passing score of over 70% on the self-assessment test, you may print out a CME credit letter awarding 1 *AMA PRA Category 1 Credit*.™ The estimated time to complete this activity is 1 hour.

ACCREDITATION AND DESIGNATION

This activity has been planned and implemented in accordance with the Essential Areas and policies of the Accreditation Council for Continuing Medical Education (ACCME) through the joint sponsorship of the Dulaney Foundation and *Advanced Ocular Care*. The Dulaney Foundation is accredited by the ACCME to provide continuing education for physicians. The Dulaney Foundation designates this educational activity for a maximum of 1 *AMA PRA Category 1 Credit*.™ Physicians should claim credit only commensurate with the extent of their participation in the activity.

DISCLOSURE

In accordance with the disclosure policies of the Dulaney

1. Donnenfeld ED, Holland EJ, Solomon KD, Fiore J, Sandoval HP. Effect of Difluprednate 0.05% and prednisolone acetate 1% on visual acuity, corneal edema, and patient satisfaction following cataract surgery. Paper presented at: The ASCRS Symposium on Cataract, IOL and Refractive Surgery; April 12, 2010; Boston, MA.

2. Nakano S, Yamamoto T, Kirii E, Abe S, Yamashita H. Steroid eye drop treatment (difluprednate ophthalmic emulsion) is effective in reducing refractory diabetic macular edema. *Graefes Arch Clin Exp Ophthalmol*. 2010;248(6):805-810.

3. DaVanzo RJ. Durezol compared to Pred Forte in the treatment of endogenous anterior uveitis. Poster presented at: The Association for Research in Vision and Ophthalmology Annual Meeting; May 3-8, 2009; Fort Lauderdale, FL.

4. Stringer W. Dose uniformity of prednisolone acetate ophthalmic suspensions compared to Durezol (Difluprednate ophthalmic suspension), 0.05%. Poster presented at: The Association for Research in Vision and Ophthalmology Annual Meeting; May 3-8, 2009; Fort Lauderdale, FL.

5. Ciulla TA, Starr MB, Masket S. Bacterial endophthalmitis prophylaxis for cataract surgery: an evidence-based update. *Ophthalmology*. 2002;109(1):13-24.

6. Baby boomers will increase demand for eye care. OSN SuperSite. November 11, 2008. Available at: <http://www.osnsuper-site.com/view.aspx?rid=32642>. Accessed July 7, 2010.

7. Mah FS. Fourth-generation fluoroquinolones: new topical agents in the war on ocular bacterial infections. *Curr Opin Ophthalmol*. 2004;15:316-320.

8. Lane SS, Osher RH, Masket S, Belani S. Evaluation of the safety of prophylactic intracameral moxifloxacin in cataract surgery. *J Cataract Refract Surg*. 2008;34(9):1451-1459.

9. Cooper BA, Holeykamp NM, Bohigian G, Thompson PA. Case-control study of endophthalmitis after cataract surgery comparing scleral tunnel and clear corneal wounds. *Am J Ophthalmol*. 2003;136(2):300-305.

Foundation and to conform with ACCME and US Food and Drug Administration guidelines, anyone in a position to affect the content of a CME activity is required to disclose to the activity participants: (1) the existence of any financial interest or other relationships with the manufacturers of any commercial products/devices or providers of commercial services; and (2) identification of a commercial product/device that is unlabeled for use or an investigational use of a product/device not yet approved.

FACULTY CREDENTIALS

Richard L. Lindstrom, MD, is the founder of and an attending surgeon at Minnesota Eye Consultants, PA, in Minneapolis, and Adjunct Professor Emeritus: University of Minnesota, Department of Ophthalmology. He may be reached at (612) 813-3600; rlindstrom@mneyc.com.



Carlos Buznego, MD, is an anterior segment surgeon at the Center for Excellence in Eye Care in Miami and a volunteer assistant professor of ophthalmology at the Bascom Palmer Eye Institute in Miami. He may be reached at (305) 598-2020; cbuz@comcast.net.



Eric D. Donnenfeld, MD, is a professor of ophthalmology at NYU and a trustee of Dartmouth Medical School in Hanover, New Hampshire. He is in private practice with Ophthalmic Consultants of Long Island in New York. Dr. Donnenfeld may be reached at (516) 766-2519; eddoph@aol.com.



Edward J. Holland, MD, is a professor of ophthalmology at the University of Cincinnati in Ohio and Director of Cornea at the Cincinnati Eye Institute. He may be reached at (859) 331-9000, ext. 3064; eholland@fuse.net.



Paul Karpecki, OD, is the clinical director of the Ocular Surface Disease Center at Koffler Vision Center in Lexington, Kentucky. He may be reached at paul@karpecki.com.



Robert H. Osher, MD, is a professor of ophthalmology at the University of Cincinnati, Medical Director Emeritus of the Cincinnati Eye Institute, and Editor of the Video Journal of Cataract and Refractive Surgery. He may be reached at (513) 984-5133, ext. 3679; rhosher@cincinnati.eye.com.



Michael B. Raizman, MD, is an associate professor of ophthalmology, Tufts University School of Medicine; Director of the Cornea and Cataract Service, New England Eye Center; and a partner at Ophthalmic Consultants of Boston. He may be reached at (617) 367-4800-2656; mbraizman@eyeboston.com.



Steven M. Silverstein, MD, is President of Silverstein Eye Centers in Kansas City, Missouri, and he is an assistant clinical

CONTENTS

- Pg. 4 Difluprednate 0.05% Emulsion: An Overview
- Pg. 7 Difluprednate Emulsion for Significant Inflammation
- Pg. 9 Routine Cataract Surgery
- Pg. 10 Treatment of Inflammation Following Cataract Surgery
- Pg. 11 Glaucoma Surgery
- Pg. 11 Corneal Grafting
- Pg. 12 Safety of Difluprednate 0.05% Emulsion
- Pg. 13 Challenges To Use

professor of ophthalmology at the University of Missouri School of Medicine and the University Health Sciences, both in Kansas City. He may be reached at (816) 358-3600; ssilverstein@silversteineyecenters.com.



FACULTY/STAFF DISCLOSURE DECLARATIONS

The faculty of this educational activity acknowledge they have received funding for speaking, consulting, and/or research from multiple companies, including the following that are relevant to the content herein.

Dr. Lindstrom: Allergan, Inc., Alcon Laboratories, Inc., and Bausch + Lomb.

Dr. Buznego: Alcon Laboratories, Inc., Allergan, Inc., Bausch + Lomb, and Sirion Therapeutics.

Dr. Donnenfeld: Allergan, Inc., Alcon Laboratories, Inc., and Bausch + Lomb.

Dr. Holland: Allergan, Inc., Alcon Laboratories, Inc., and Bausch + Lomb.

Dr. Karpecki: Bausch + Lomb, Alcon Laboratories, Inc., and Allergan, Inc.

Dr. Osher: Alcon Laboratories, Inc.

Dr. Raizman: Alcon Laboratories, Inc., Allergan, Inc., and Bausch + Lomb.

Dr. Silverstein: Alcon Laboratories, Inc., Allergan, Inc., Bausch + Lomb, and Ista Pharmaceuticals, Inc.

Jodi Luchs, MD, being involved in the peer review of this educational activity, is a consultant and/or speaker for or has received research support from Allergan, Inc., Inspire Pharmaceuticals, Inc., and Ista Pharmaceuticals, Inc.

David W. Friess, OD, being involved in the planning, editing, or peer review of this educational activity, is a consultant for TrueVision Systems, Inc., Alcon Laboratories, Inc., and DurrieVision P.A.

All others involved in the planning, editing, and peer review of this educational activity have indicated they have no financial relationships to disclose.

Corticosteroids and Anterior Segment Inflammation

Difluprednate 0.05% Emulsion: An Overview

BY RICHARD L. LINDSTROM, MD

With the increasing demand for efficient delivery of care to a rapidly aging population, the need for advanced pharmaceutical tools to aid in the treatment of ocular inflammation is greater than ever.¹ For more than 6 decades, topical corticosteroids have been the cornerstone of therapy for the treatment of various forms of ocular inflammation, both surgical and autoimmune in nature.² By inhibiting the release of phospholipase A2 early in the inflammatory cascade, steroids provide a broad range of anti-inflammatory activity by attenuating the effects of inflammatory mediators and preventing their release. Despite steroids' ubiquity in the treatment of inflammation, relatively little innovation in this class of drug has occurred in terms of therapy for moderate-to-severe inflammation. In late 2008, however, difluprednate ophthalmic emulsion 0.05% (Durezol; Alcon Laboratories, Inc., Fort Worth, TX) was approved for the treatment of inflammation and pain associated with ocular surgery. This welcome new addition to the collection of approved potent corticosteroids for managing ocular inflammation presents a new opportunity for ophthalmologists and anterior segment surgeons to update their treatment strategies in consideration of other pharmaceutical options. This article provides an overview of difluprednate's history and current data.

DEVELOPMENT OF DIFLUPREDNATE

For more than 3 decades, a novel potent steroid has not been introduced in the U.S. The most recent steroid to come to market in this country was loteprednol (Lotemax; Bausch + Lomb, Rochester, NY), which was formulated to cause less frequent and intensive IOP spikes and therefore was considered safer than previous steroids. The difluprednate molecule was originally developed by

Mitsubishi Chemical Holdings Corporation (Tokyo, Japan) to be a dermatologic agent (Figure 1). It is classified as a very strong steroid in dermatology.^{3,4} Subsequently, Senju Pharmaceutical Co., Ltd. (Osaka, Japan) formulated an ophthalmic preparation of difluprednate and determined that an emulsion formulation was optimal because of greater bioavailability.⁵ Much of the drug's original ophthalmologic research was also conducted in Japan, where they do not have access to prednisolone acetate. As such, their comparative steroid in the difluprednate trials was betamethasone, which on a molecular basis has a 6-fold anti-inflammatory potency when compared to prednisolone.⁶ The Japanese are known for being reliable, academic observers and cautious with their claims. Preclinical studies demonstrated that difluprednate was safe and could achieve high concentrations in the cornea, aqueous, and ciliary tissues.⁷⁻¹⁰ In human studies, researchers found difluprednate 0.05% emulsion to be as potent as betamethasone, particularly when treating uveitis.¹¹ In addition, the emulsion dosed q.i.d. was effective at treating refractory uveitis patients who had failed on betamethasone dosed 8 to 12 times per day.¹²

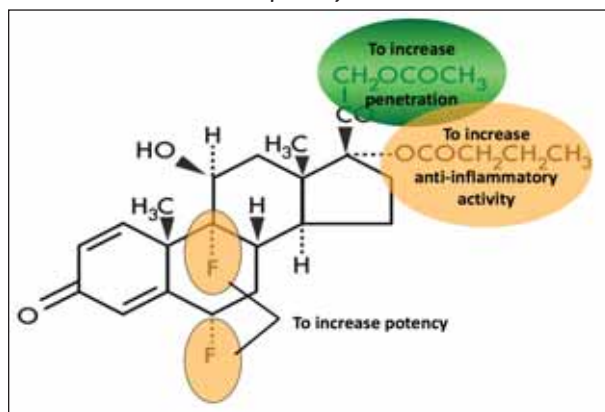


Figure 1. Difluprednate, a difluorinated derivative of prednisolone, was purposely engineered to achieve maximum efficacy. The addition of two fluorine groups make the molecule more potent. Other structural modifications help to increase the drug's corneal penetration and enhance its anti-inflammatory activity.

FORMULATION

Difluprednate 0.05% emulsion has been shown to provide consistent dosing of medication when compared to prednisolone acetate suspension formulations.¹³ This is not surprising, since suspensions have a tendency to separate. Studies have shown that some suspensions require shaking the bottle 20 to 30 times to thoroughly mix the drug with the vehicle.^{8,9} Compliance studies have shown that it is extremely rare for patients to shake the bottle 20 to 30 times before they use the drop. Emulsions do not require such mixing before use.

In addition, difluprednate emulsion does not contain the preservative benzalkonium chloride, which has shown ocular toxicity in some studies.¹⁴⁻¹⁶ Instead, it is preserved with with sorbic acid, which has been demonstrated to cause little damage to ocular tissue or irritation and is recommended for sensitive eyes.¹⁷

DATA

Indication

Based upon the extensive clinical work that Senju completed with difluprednate 0.05% emulsion, it was clear that the drug could provide a significant advantage over current steroid therapies in the U.S. (see Table 1 for alternative treatments). The steroid gained FDA approval in June 2008 for the treatment of pain and inflammation associated with ocular surgery. Two phase 3 trials showed that it was particularly effective dosed either b.i.d. or q.i.d. at decreasing inflammation and pain following ocular surgery in patients presenting with more than 10 cells in the anterior chamber. Difluprednate 0.05% emulsion dosed q.i.d. has also been tested against prednisolone acetate dosed eight times per day in the treatment of anterior uveitis. This study demonstrated that these two regimens were comparable at reducing inflammation.

Efficacy Study

To gain FDA approval, an anti-inflammatory drug must demonstrate efficacy versus a placebo. Difluprednate 0.05% emulsion's efficacy study was conducted at 26 sites and comprised 438 subjects who were randomized into three groups.¹⁸ Group one (n=111) took the drug twice a day for 2 weeks and then once per day for 2 weeks. Group two (n=107) took the drug four times per day for 2 weeks, twice a day for 1 week, and once per day for 1 week. Group three (n=220) took the placebo, which was dosed in both a b.i.d. and q.i.d. fashion.

The efficacy study's enrollment criterion was moderate inflammation after cataract surgery. Patients who were identified as having more than 10 cells per high-powered field were enrolled in the study and then randomized into these three groups.

Difluprednate 0.05% emulsion showed a statistically significant improvement in the clearing of ocular inflammation (defined as 1 or no cells) (Figure 2). The steroid demonstrated efficacy at clearing inflammation at days 3, 15, and 29 with both dosing regimens and with no statistically significant difference between them (although the mean numbers showed a slightly greater efficacy with q.i.d. dosing compared with b.i.d. dosing). Thus, difluprednate 0.05% emulsion may be just as effective when used less frequently, a regimen that would be easier for most cataract patients to adhere to. Difluprednate 0.05% emulsion also reduced secondary endpoints such as corneal edema, swelling of the conjunctiva, pain (using an analog scale), and photophobia. Impressively, the agent significantly improved all these endpoints regardless of the dosing.

Adverse Events

In the q.i.d. dosing group, 2.8% of patients experienced clinically significant elevated IOP (defined as greater than

TABLE 1. OPHTHALMIC CORTICOSTEROID TREATMENT OPTIONS

Drug	FDA-Approved Indication
Difluprednate 0.05% emulsion	Treatment of inflammation and pain associated with ocular surgery
Loteprednol etabonate 0.5%	Treatment of steroid-responsive inflammatory ocular conditions of the palpebral and bulbar conjunctiva, cornea, and anterior segment of the globe as well as for the treatment of postoperative inflammation following ocular surgery
Prednisolone acetate 1%	Treatment of steroid-responsive inflammatory ocular conditions of the palpebral and bulbar conjunctiva, cornea, and anterior segment of the globe

or equal to 21 mm Hg and change from baseline of greater than or equal to 10 mm Hg at the same visit) (Table 2). IOP elevation in the b.i.d. dosing group was 2.7%. The placebo group, by comparison, saw a rise in IOP in only 0.9% of patients. Difluprednate 0.05% emulsion is a potent steroid and therefore may cause a rise in IOP in steroid responders or patients with a family history of glaucoma, much like prednisolone acetate.

While both dosing regimens were effective at reducing many signs of inflammation when compared to placebo, the q.i.d. regimen was numerically better than the b.i.d. one at reducing pain.

Uveitis Study

Investigators conducted a 90-patient noninferiority study to compare the difluprednate 0.05% emulsion q.i.d. with prednisolone acetate 1% (Pred Forte; Allergan, Inc., Irvine, CA) dosed eight times per day. Patients were randomized between difluprednate 0.05% emulsion (n=50) and prednisolone acetate 1% (n=40) at 20 sites. The inclusion criteria were moderate anterior uveitis (e.g., more than 10 cells per high power field) and a flare grading of 2 or more. The difluprednate group was treated q.i.d. for 2 weeks, and twice per day for 1 week, once a day for 1 week, and then every other day. Patients in the prednisolone acetate group were dosed twice as frequently at the same intervals. The noninferiority hypothesis was met, proving that difluprednate 0.05% emulsion dosed q.i.d. was comparable to prednisolone acetate dosed eight times per day at reducing inflammation in patients with moderate-to-severe uveitis. For several other measures, difluprednate emulsion was numerically superior to prednisolone acetate (Figure 3).

No withdrawals contributed to lack of efficacy were reported in the difluprednate group, although the rate was 12.5% in the prednisolone acetate group (despite its more frequent dosing). The eyes that received difluprednate 0.05% emulsion had better BCVA at all time points

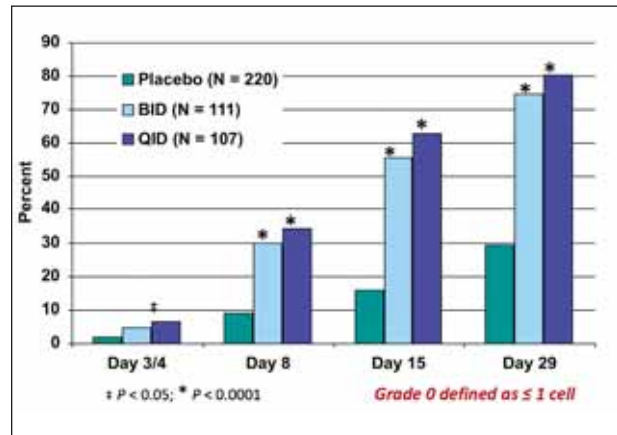


Figure 2. Percentage of subjects with clearing of anterior chamber cells. The primary endpoint was the proportion of subjects with an anterior chamber cell grade of “0” (one or no cells) on day 8. At day 8, 30% of patients on difluprednate b.i.d. and 35% on difluprednate q.i.d. had one or no cells, compared with 9% in the placebo group. These percentages increased to 56%, 63%, and 16% by Day 15, respectively.

and numerically superior results on eight of the 11 domains on the VFQ-25 and all domains on the Work Limitations Questionnaire.¹⁹

IOP AND OTHER ISSUES

The risk of increased IOP is a legitimate concern with a strong steroid such as difluprednate 0.05% emulsion. In the uveitis study, patients treated with difluprednate experienced a clinically significant IOP rise (defined as greater than or equal to 21 mm Hg and change from baseline of greater than or equal to 10 mm Hg at the same visit) in 6% of patients compared with 5% of the eyes treated with prednisolone acetate.

As with all steroids, especially potent ones, the formation of secondary cataracts is a concern. Also, cost may prove an issue for surgeons and patients alike.

TABLE 2. PERCENT OF SUBJECTS WITH CRITERION INCREASE* IN INTRAOCULAR PRESSURE

	Difluprednate b.i.d. (N = 111)	Difluprednate q.i.d. (N = 107)	Placebo b.i.d. & q.i.d. (N = 220)
Subjects, n	3	3	2
Subjects, %	2.7	2.8	0.9

* Defined as ≥ 21 mm Hg and change from baseline ≥ 10 mm Hg at the same visit.

BENEFITS OF DIFLUPREDNATE

Based on the available data, the most likely potential uses for difluprednate 0.05% emulsion are any setting in which there is significant inflammation. The drug may not be necessary for routine cataract surgery, but it may make sense for eyes at risk for inflammation and cystoid macular edema (CME), such as those with a history of uveitis, diabetes mellitus, CME prior to surgery, or glaucoma, or corneal grafts. I would also consider using difluprednate 0.05% emulsion in patients with a history of retinal problems (eg, retinal membrane, pigmentary retinopathy, macular degeneration). This drug would be useful in retinal detachments and vitrectomies, which carry a higher risk of inflammation. Of course, any cataract operation in which the eye develops severe inflammation or toxic anterior segment syndrome would likely benefit from the difluprednate emulsion. In laser refractive surgery, difluprednate 0.05% emulsion may be a good choice for treating diffuse lamellar keratitis.

In summary, difluprednate 0.05% emulsion appears to be a promising addition to the surgical armamentarium for treating a wide range of ocular inflammatory conditions. In the following pages, surgeons who have been using the drug since the FDA trials will describe their early experience and observations.

References listed on page 13.

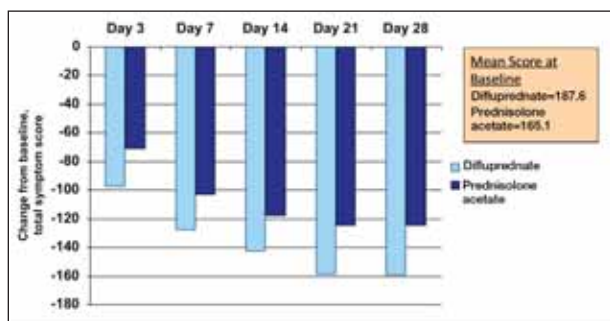


Figure 3. Mean change from baseline in total symptom score.* At day 14, difluprednate patients showed a larger mean reduction (76%) than prednisolone acetate subjects (71%). This trend was maintained through day 42 with the difluprednate group, demonstrating a total symptom score reduction of 86%, vs 76% for prednisolone acetate. It is important to note that the difluprednate group started with a higher mean total symptom score than the prednisolone acetate group. *The total symptom score was the sum of pain/ocular discomfort, photophobia, blurred vision, and lacrimation. Each symptom was graded using a visual analogue scale that ranged from 0 to 100. Patients were asked to assess these symptoms by marking on a 100-mm line where 0 = absent and 100 = maximal.

Difluprednate Emulsion for Significant Inflammation

EDWARD J. HOLLAND, MD

This section describes an off-label use of difluprednate 0.05% emulsion.

The major concern ophthalmologists face when performing corneal and conjunctival surgery is inflammation. Therefore, surgical success depends on reducing the postoperative inflammatory reaction as much as possible. Ocular surgeries that are associated with a high rate of postoperative inflammation include corneal transplantation (eg, penetrating keratoplasty, Descemet's stripping automated endothelial keratoplasty, deep anterior lamellar keratoplasty), lamellar patch grafts, ocular surface transplantation, and pterygium surgery.

Ocular Surface Surgery

My staff and I perform a significant number of stem cell surface transplants. These patients suffer from conditions that affect the limbal and sometimes the conjunctival stem cells. Their diagnoses include chemical and thermal injuries and conditions involving severe autoimmune conjunctivitis, such as Stevens-Johnson syndrome, ocular cicatricial pemphigoid, and severe Sjögren's syndrome. These types of patients are often maintained on frequently dosed topical steroids or a triple oral immune suppression system. Many of them suffer chronic inflammation or chronic rejection.

Since switching these patients from prednisolone acetate 1% to difluprednate 0.05% emulsion, I have seen their ocular surfaces respond positively, with less inflammation in the postoperative period.

CME

I have also used this drop to treat CME (an off-label use of the drug). I treat these eyes with a combination of an NSAID and a steroid, and I have begun using difluprednate 0.05% emulsion in place of prednisolone acetate 1% in this combination. Although difluprednate 0.05% emulsion has not yet undergone a clinical study of for this indication, using it in these cases makes sense, as it is the most potent steroid available, and I have had good results with the treatment regimen.

Conjunctival Surgery

Additionally, I use difluprednate 0.05% emulsion for anyone who has undergone conjunctival surgery, which

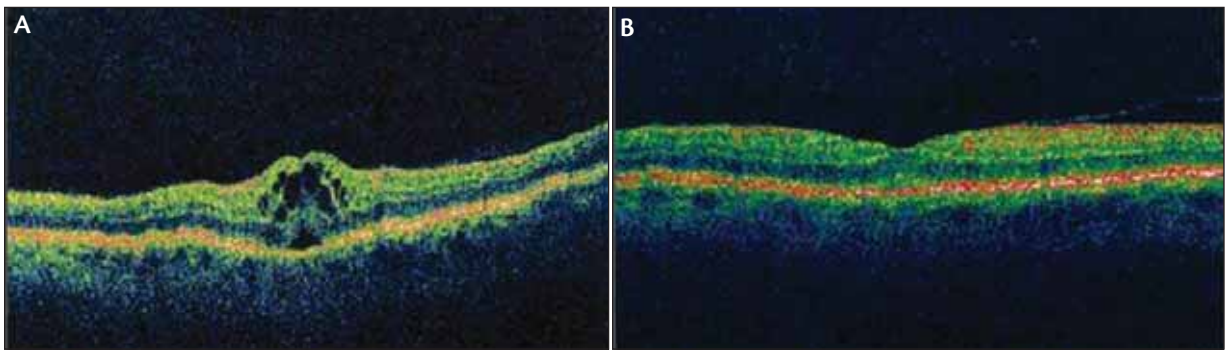


Figure 4. OCT images of an eye with clinically significant CME. Before treatment with difluprednate emulsion (A; 4 weeks postoperatively), the eye's BCVA was 20/30; 20/70 with glare testing. Its retinal thickness was 537 μm . After treatment with difluprednate emulsion (B), the BCVA was 20/20 and the retinal thickness was 214 μm .

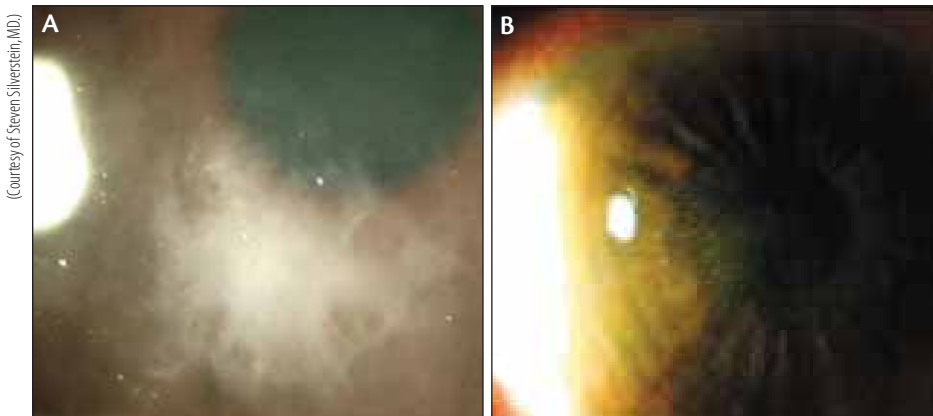


Figure 5. Diffuse lamellar keratitis (A) resolved after treatment with difluprednate emulsion 0.05% (B).

commonly induces inflammation. The most common conjunctival surgery I perform is pterygium excision with a conjunctival autograft. The biggest threat these patients face is recurrence of the pterygium, because recurrent disease is associated with significant inflammation that is difficult to manage.

MICHAEL B. RAIZMAN, MD

This section describes an off-label use of difluprednate 0.05% emulsion.

In my experience, difluprednate 0.05% emulsion requires about half of the dosing of prednisolone acetate 1%. I can use the former every 4 hours to control inflammation in situations that would require prednisolone acetate 1% every 2 hours. I mainly prescribe difluprednate 0.05% emulsion when patients need to use a steroid drop frequently (such as for uveitis;¹⁹ an off-label use), because its dosing schedule is much more convenient than weaker steroids. In cases of severe

inflammation, I may administer difluprednate emulsion every hour to achieve a maximal effect.

I have treated some patients with uveitis who did not respond to prednisolone acetate, but they did respond to difluprednate 0.05% emulsion. Again, I attribute this response to the potency of the difluprednate molecule. The steroid's chemical nature seems to suppress inflammation better

than prednisolone acetate and with less frequent dosing.¹⁰ I also use it to treat corneal graft rejections for this reason.

STEVEN M. SILVERSTEIN, MD

This section describes an off-label use of difluprednate 0.05% emulsion.

I believe in using the most powerful ophthalmic steroidal agent initially to prevent complications of inflammation from forming. For individuals who are at a high risk of developing complications of inflammation such as capsular tears, epiretinal membranes, CME (Figure 4), or who have a prior history of retinal surgery, uveitis, or other pathologies, I prescribe difluprednate 0.05% emulsion either q.i.d. or every 2 hours for the first week and then b.i.d. for an additional 2 to 3 months. Figure 5A and B shows an eye with diffuse lamellar keratitis that resolved after treatment with difluprednate emulsion 0.05%.

Routine Cataract Surgery

ROBERT H. OSHER, MD

I decided to use difluprednate 0.05% emulsion in my routine cataract patients, because I cannot predict which ones will have postoperative inflammation, aching, or (rarely) CME. If I can preempt unexpected outcomes, which occur infrequently, in my routine patients by switching to this drop, then it seems reasonable as long as the benefits outweigh the risk.

My patients usually enjoy excellent uncorrected vision within 24 hours postoperatively, because I am a meticulous surgeon and I use my gentle slow-motion phaco technique beneath an ophthalmic viscosurgical device, which minimizes inflammation inside the eye. Nevertheless, after using difluprednate 0.05% emulsion, I noticed that even these patients had very little cell and flare, minimal vascular injection, or rarely any aching that may accompany uncomplicated cataract surgery on the first day or two. Also absent were some of the symptoms observed with normal inflammation, namely light sensitivity, pupillary miosis, and ciliary flush. So, from testing difluprednate 0.05% emulsion in my worst case, I ended up using it in all my surgeries.

I usually prescribe difluprednate emulsion postoperatively

in a tapering regimen for 1 month, although 3 weeks is probably plenty. Then, I transition the patient to an NSAID for another few weeks, since the peak incidence of CME occurs between 3 and 6 weeks after surgery.²⁰ I tend to overtreat; I would rather prevent the patient from developing an issue. We need formal studies to compare a 1-month tapering regimen of difluprednate 0.05% emulsion versus a shorter, high-dose regimen. I suspect that briefer regimens may eventually become the standard of care for steroids.

STEVEN M. SILVERSTEIN, MD

I am confident using difluprednate 0.05% emulsion in routine, low-risk cataract patients, because it keeps their eyes comfortable in the early postoperative period, and I prefer to address inflammation prophylactically rather than treating it after the fact. I prescribe a b.i.d. regimen for routine patients and a q.i.d. regimen for those with more pronounced corneal edema and inflammation. I have them finish one bottle of the emulsion at this dosage. Difluprednate's clinical trial on postcataract inflammation confirmed that the drug works as effectively dosed b.i.d. as q.i.d.¹⁸ These findings will reassure practitioners that if patients do not comply with q.i.d. dosing, they will still experience a benefit if they use the drop twice per day.

CASE EXAMPLE: SIGNIFICANT INFLAMMATION

BY ROBERT H. OSHER, MD

Based on the outcomes of the anterior segment uveitis clinical trial for difluprednate 0.05% emulsion,^{11,12} I decided to try it in my worst patient. In 1993, a 50-year-old Canadian female underwent complicated cataract surgery in the left eye. She had experienced a broken posterior capsule and vitreous herniated into the anterior segment. She developed angle-closure glaucoma that necessitated laser, vitreolysis, and peripheral iridotomies. Then, she developed severe glaucoma and underwent three holmium laser treatments. When this patient was referred to me in 1993, I explanted her anterior chamber lens, managed her vitreous and residual cortex, and implanted a posterior-chamber IOL using capsular remnants. One of my partners performed a filtering procedure with releasable sutures at the same time. At the 2-week follow-up visit, the patient's vision had returned to 20/20 UCVA, and her IOP was normal. Unfortunately, she suffered from chronic inflammation and irritation in that eye for the next 16 years. Her oph-

thalmologist in Canada had treated the eye with every known steroid and anti-inflammatory agent, but the chronic discomfort persisted.

I asked my contacts at Sirion Therapeutics (Tampa, FL) if they would assist in sending difluprednate 0.05% emulsion to this patient in Canada through a special drug importation exemption, since it is not currently available outside of the US. Approximately 24 hours after this patient received the samples, she called me, ecstatic, and declared that for the first time in 16 years, her eye was completely comfortable.

Witnessing the efficacy of difluprednate 0.05% emulsion in this patient made me reconsider my steroidal routine in high-risk patients. Previously, I would administer a periocular steroid injection in eyes that had a preoperative epiretinal membrane, diabetic retinopathy, CME, or a history of uveitis. I started to give these patients difluprednate 0.05% emulsion instead, and I noticed that their postoperative inflammation was minimal.

Treatment of Inflammation Following Cataract Surgery

ERIC D. DONNENFELD, MD

I participated in an investigator-initiated study to evaluate the efficacy of pre- and postoperative dosing of difluprednate 0.05% versus prednisolone acetate 1% on postoperative UCVA, BCVA, IOP, corneal pachymetry, endothelial cell count, and retinal thickening (measured by OCT) following phacoemulsification. More generally, we wanted to evaluate how quickly the patients regained visual function after cataract surgery when they used difluprednate emulsion versus conventional therapy with prednisolone acetate. This interim analysis is part of an ongoing study that will enroll 67 patients and include an assessment of patients' postoperative satisfaction.

Parameters

My co-investigators were Edward J. Holland, MD, of Cincinnati, and Kerry Solomon, MD, of Mt. Pleasant, South Carolina. We conducted an observer-masked, self-controlled, paired comparison with 39 patients (78 eyes) who underwent uncomplicated bilateral cataract surgery 2 weeks apart. We randomized each patient's eyes so that one received difluprednate 0.05% emulsion and the other eye received prednisolone acetate 1%. We based the dosing schedule on the data from preliminary trials we conducted which indicated that patients should receive at least 10 drops on the day of surgery.²¹ We asked them to begin using the drops 1 hour before surgery at a dose of four drops every 15 minutes. At the surgery center, they applied three drops 15 minutes apart before their surgery. Postoperatively, subjects took

three more drops every 15 minutes for the first hour and then every 2 hours thereafter. They continued q.i.d. dosing for 1 week followed by b.i.d. dosing for the second postoperative week.

Outcomes

We theorized that because the pulsed dosing of very potent corticosteroids protects brain tissue after traumatic brain injury, and the corneal endothelium is of neuroectodermal origin, that giving eyes pulsed, high doses of corticosteroid preoperatively would protect the endothelium and reduce the incidence of corneal edema on the first postoperative day. As confirmation, a statistically significantly greater number of the difluprednate-treated eyes saw 20/20 BCVA on the first postoperative day versus those in the prednisolone acetate group—almost four to one (Table 3). The eyes in the difluprednate emulsion group also had thinner corneas (by 40 μm, on average) (Figure 6) versus the prednisolone acetate-treated eyes. These trends proved sustainable: the difluprednate-treated eyes showed less endothelial cell loss through day 30 than the prednisolone acetate-treated eyes (Figure 7). In essence, the difluprednate 0.05% emulsion eyes experienced a faster return of vision and measurably less damage to the cornea than the prednisolone acetate group.

Furthermore, we tested postoperative IOP and retinal thickness between the medications. We found no significant difference in mean IOP between the two groups (Figure 8). At days 15 and 30, the eyes that received difluprednate showed significantly thinner retinas versus the prednisolone acetate group (Figure 9).

This trial is ongoing. We expect to present the final data in about 3 months. Thus far, most results have been statistically significant in favor of difluprednate 0.05% emulsion.

TABLE 3. BCVA, DAY 1

	Difluprednate emulsion	Prednisolone acetate	P-value
20/15 or better	1 (2.56%)	0	n/a
20/20 or better	19 (48.72%)	5 (12.82%)	0.0005
20/30 or better	34 (87.18%)	20 (51.28%)	0.0005
20/40 or better	37 (94.87%)	33 (84.62%)	0.1025
20/70 or better	39 (100%)	38 (97.44%)	n/a

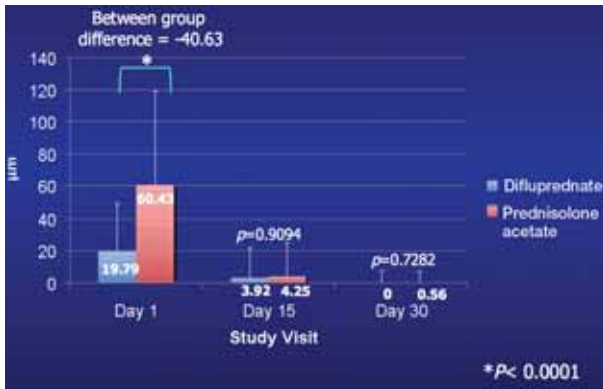


Figure 6. Postoperative clinical trial data: corneal pachymetry change from baseline.

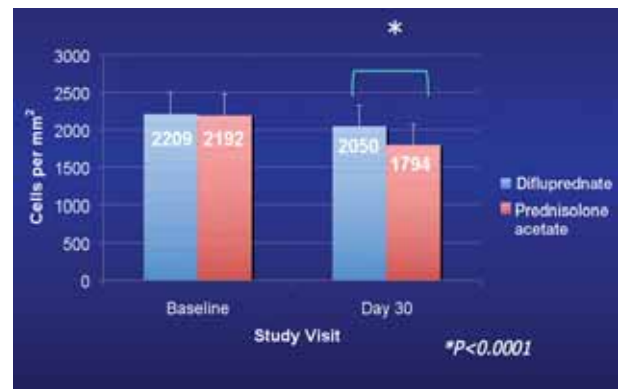


Figure 7. Postoperative clinical trial data: mean specular microscopy.

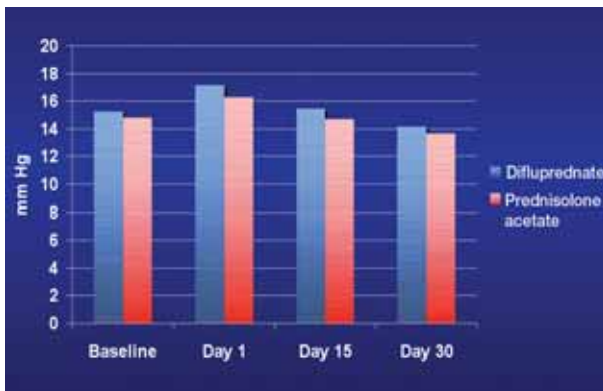


Figure 8. Postoperative clinical trial data: mean IOP.

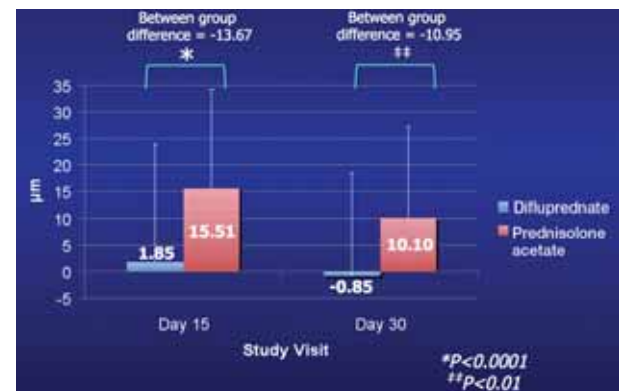


Figure 9. Postoperative clinical trial data: central retinal thickness change from baseline.

Glaucoma Surgery

CARLOS BUZNEGO, MD

Based on the outcomes from its uveitis clinical trial, I believe that difluprednate 0.05% emulsion is a valuable steroid that is especially suited for patients with glaucoma who have unique issues that increase their risk for inflammation. This heightened incidence of inflammation in these eyes may be due to postsurgical anatomical issues or to the use of prostaglandin analogs to lower IOP. In particular, inflammation may trigger late bleb failure in patients who have undergone prior trabeculectomy. The pupils of glaucomatous eyes often dilate poorly or may have synechia from prior surgery—conditions that can complicate cataract surgery. Pupillary stretching or iris manipulation is often necessary during cataract surgery. These maneuvers trigger a breakdown of the blood-aqueous barrier and further increase the risk of inflammation postoperatively.

In glaucomatous patients, I usually dose difluprednate 0.05% emulsion in a q.i.d. regimen for at least 4 weeks, followed by a b.i.d. schedule for 2 to 4 more weeks. In patients with severe inflammation, I often institute a regimen of every 2 hours to more rapidly resolve the inflammation.

Significant IOP spikes have been anecdotally reported with the use of difluprednate 0.05% emulsion. As with the use of any steroid, glaucoma patients' IOP must be diligently monitored in case they are "steroid responders."

Corneal Grafting

EDWARD J. HOLLAND, MD

At the time when difluprednate 0.05% emulsion became available, I had a couple of patients who were chronically rejecting their grafts after penetrating keratoplasty (Figure 10). The first patient in whom I tried difluprednate 0.05% emulsion was diagnosed with pellucid

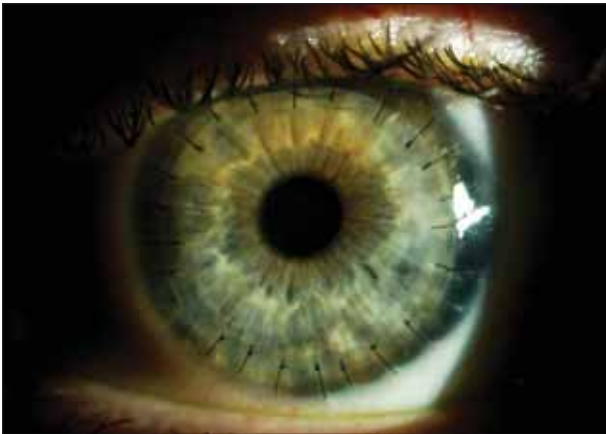

Figure 10. An eye 6 months after undergoing penetrating keratoplasty and treatment with difluprednate 0.05% emulsion.

marginal degeneration and required large-diameter (9.5 mm) bilateral grafts. She chronically rejected the grafts in both eyes and developed keratic precipitates in her cornea, neovascularization, and corneal edema.

At first, I prescribed this patient prednisolone acetate on an hourly basis. The inflammation persisted, so I added oral mycophenolate. She continued to chronically reject the grafts, so I switched her to difluprednate 0.05% emulsion as soon as it was made available. Within a matter of days, this patient's inflammation improved. Her keratic precipitates vanished, and the neovascularization in the periphery of her transplant regressed over the next several

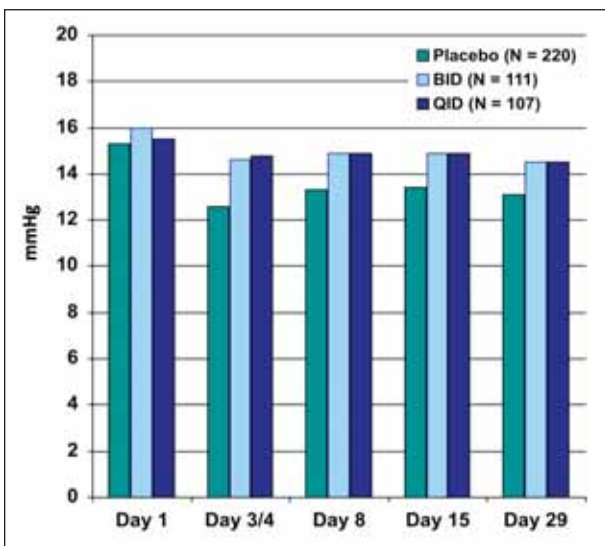


Figure 11. In the postcataract trial of difluprednate 0.05% emulsion, subjects' mean IOP remained within a normal range throughout the study period.¹⁸

weeks. This patient's condition improved so much that I discontinued the mycophenolate and decreased the dosing regimen of the difluprednate emulsion to q.i.d., which I tapered to b.i.d. over a 4-month period.

The eyes of a couple more of my patients for whom I prescribed frequently dosed steroids because of their recurrent rejection reactions also quieted down with difluprednate 0.05% emulsion. My dosing regimen for all types of corneal transplants is q.i.d. for about 3 months postoperatively before I transition patients (if they are doing well) to loteprednol etabonate drops (Lotemax; Bausch + Lomb, Rochester, NY).

Safety of Difluprednate 0.05% Emulsion

ROBERT H. OSHER, MD

One would expect a stronger steroid to have greater side effects than weaker agents. Response data on difluprednate 0.05% emulsion shows that its effect on IOP is within an acceptable range (Figure 11).^{18,19} Even if this drop raises IOP, it does not need to be used as long as other steroids. Steroid response takes time to develop.

I prefer to treat inflammation aggressively. I will measure the IOP in my patients at the 3-week visit for any reaction to a steroid before discontinuing its use. Anecdotally, I do not think there have been more IOP spikes with difluprednate 0.05% emulsion than with prednisolone acetate 1%, but I have not studied this formally. I recall several patients with elevated IOP when they come in for their 3-week visit, but by then they have begun tapering the steroid, and their IOP is back to normal by their next visit. Difluprednate 0.05% emulsion has consistently performed safely and efficaciously in my practice.

STEVEN M. SILVERSTEIN, MD

Every clinician is concerned about patients who are susceptible to IOP spikes (steroid responders), particularly with an ophthalmic steroid as strong as difluprednate 0.05%. In my experience, the incidence and severity of IOP spikes with this emulsion are similar to those reported with other steroids. IOP spikes I have seen related to this drug are usually between 30 and 40 mm Hg, and occasionally higher, but discontinuing usage rapidly returns the eye to its normal IOP. During the q.i.d. and b.i.d. dosing clinical trials for difluprednate 0.05% emulsion, mean IOP remained in the normal range (Figure 11).

Challenges to Use

ROBERT H. OSHER, MD

The most significant challenges I face in using difluprednate 0.05% emulsion have been accessibility and cost. Some pharmacies still do not carry it, although I have made calls in my area to try to change that. Second, although this drop costs a lot more than the giveaway steroid, so did sodium hyaluronate ophthalmic viscoelastic device (Healon; Abbott Medical Optics Inc., Santa Ana, CA) compared to air when it was first introduced. In the early days of phacoemulsification, I heard the argument that such an expensive technology would never replace cheap and fast extracapsular cataract extraction. I always knew, however, that ophthalmologists would eventually embrace a superior product. I predict it will be the same with difluprednate 0.05% emulsion. Per inflammatory cell, this emulsion is fairly cheap. Patients only undergo surgery on their eyes once, so they may be willing to pay a little more for a premium steroid. ■

1. Harmon D, Freeman W. The Surgeon's Quarterly Survey Report: Q1 2008. St. Louis, MO: Marketscope, LLC; June 30, 2008.
2. Corboy JM. Corticosteroid therapy for the reduction of postoperative inflammation after cataract extraction. *Am J Ophthalmol*. 1976;82(6):923-927.

3. Furue M, Kohno Y, Yamamoto S, et al; The Research Group for Therapeutic Guideline Construction on Atopic Dermatitis. Therapeutic guidelines for atopic dermatitis 2002. *Allergy International*. 2005;54:45-49.
4. World Health Organization (WHO). The Anatomical Therapeutic Chemical (ATC) classification system. Available at: <http://apps.who.int/medicinedocs/en/d/Js4875e/14.html>. Accessed June 23, 2010.
5. Inoue J, Yamaguchi M, Sakaki H, et al. Preclinical pharmacokinetics of difluprednate emulsion. Poster 2651, program B741. Presented at: The ARVO Annual Meeting; May 8, 2007; Ft. Lauderdale, FL.
6. Schimmer BP, Parker KL. Adrenocortical steroids and their synthetic analogs; inhibitors of the synthesis and actions of adrenocortical hormones. In: Hardman JG, Limbird LE, Gilman, AG, eds. *Goodman & Gilman's The Pharmacological Basis of Therapeutics*. 10th ed. McGraw-Hill, New York, NY; 2001.
7. Sakaki H, Mito C, Nemoto S, et al. Preclinical toxicity of difluprednate ophthalmic emulsion. Poster B743, program 2653. Presented at: The ARVO Annual Meeting; May 8, 2007; Ft. Lauderdale, FL.
8. Tajika T, et al. Ocular distribution and metabolism after instillation of difluprednate ophthalmic emulsion in rabbits. Poster B744, program 2654. Presented at: The ARVO Annual Meeting; May 8, 2007; Ft. Lauderdale, FL.
9. Kida T, et al. Difluprednate emulsion inhibits postoperative inflammation in rabbit paracentesis model. Poster B745, program 2655. Presented at: The ARVO Annual Meeting; May 8, 2007; Ft. Lauderdale, FL.
10. Ohji M, et al. Efficacy and safety results of a phase III study of difluprednate ophthalmic emulsion (DFBA), 0.05%, in post-operative inflammation. Poster B807, program 3903. Presented at: The ARVO Annual Meeting; May 8, 2007; Ft. Lauderdale, FL.
11. Okumura A, et al. Efficacy of difluprednate ophthalmic emulsion in preclinical studies of uveitis. Poster B742, program 2652. Presented at: The ARVO Annual Meeting; May 8, 2007; Ft. Lauderdale, FL.
12. Mochizuki M, Ohno S, Usui M, et al; DFBA Study Group. A phase III, open-label, clinical study of difluprednate ophthalmic emulsion (DFBA), 0.05%, in the treatment of severe refractory uveitis. Poster B809, program 3905. Presented at: The ARVO Annual Meeting; May 8, 2007; Ft. Lauderdale, FL.
13. Stringer W, Bryant R. Dose uniformity of prednisolone acetate ophthalmic suspensions compared to Durezol™ (difluprednate ophthalmic emulsion), 0.05%. Poster A351, program 1461. Presented at: The ARVO Annual Meeting; May 4, 2009; Ft. Lauderdale, FL.
14. Epstein SP, Chen D, Asbell PA. Evaluation of biomarkers of inflammation in response to benzalkonium chloride on corneal and conjunctival epithelial cells. *J Ocul Pharmacol Ther*. 2009;25(5):415-424.
15. Khoh-Reiter S, Jessen BA. Evaluation of the cytotoxic effects of ophthalmic solutions containing benzalkonium chloride on corneal epithelium using an organotypic 3-D model. *BMC Ophthalmol*. 2009;28:9:5.
16. Tripathi BJ, Tripathi RC, Kollis SP. Cytotoxicity of ophthalmic preservatives on human corneal epithelium. *Lens Eye Toxic Res*. 1992;9(3-4):361-375.
17. Abelson MB, Washburn S. The downside of tear preservatives. *Review of Ophthalmology*. 2002;9(5).
18. Korenfeld M, Silverstein S, Cooke, D, et al. Difluprednate ophthalmic emulsion 0.05% for postoperative inflammation and pain. *J Cataract Refract Surg*. 2009;35(1):26-34.
19. DaVanzo RJ. Durezol™ compared to Pred Forte® in the treatment of endogenous anterior uveitis. Poster D1106, program 2697. Presented at: The ARVO Annual Meeting; May 4, 2009; Ft. Lauderdale, FL.
20. DeCroos FC, Afshari NA. Perioperative antibiotics and anti-inflammatory agents in cataract surgery. *Curr Opin Ophthalmol*. 2008 Jan;19(1):22-26.
21. Eric Donnenfeld ED, Holland EJ, Solomon KD, et al. The effect of difluprednate 0.05% compared to prednisolone acetate 1% on visual acuity, corneal edema and patient satisfaction following cataract surgery. Paper presented at: The ASCRS Annual Meeting; May 10, 2010; Boston, MA.

DIFLUPREDNATE 0.05% EMULSION IN AN OPTOMETRIC PRACTICE

BY PAUL KARPECKI, OD

Treating anterior-segment inflammatory eye disease is a large part of my optometric practice, and I am glad to now have a strong steroid for this purpose. Difluprednate 0.05% emulsion is unequivocally my first choice to treat uveitis and similar pathology. This drug plays an integral role in my six steps for managing iritis.

1. Rule out keratouveitis. The presence of this condition changes the entire treatment strategy.
2. Treat aggressively. I believe in countering ocular inflammation with the most aggressive treatment I can, whether via high dosing with a weaker steroid, or preferably (for compliance reasons) a stronger steroid dosed less frequently. I have seen difluprednate 0.05% emulsion act immediately on severe cases of inflammation. One of my patients presented with 300° of synechia and grade 3 to 4 cell and flare, almost plasmoid, and his eye responded very well to this emulsion.
3. Check IOP. Sometimes, patients with trabeculitis can experience elevated IOP.
4. Rule out systemic causes of inflammation in recurrent or bilateral cases.
5. Rule out previous surgery, which may point to endophthalmitis.
6. Treat beyond the cell and flare to restore the blood-

aqueous barrier.

I have had great success with managing ocular inflammation by following this protocol. This drug is aggressive when I need a strong steroid, but I can also taper it and use it for a prolonged duration to prevent inflammation from rebounding. I am able to prescribe this drop at half the dosing I prescribe for other steroids and still get the same efficacy. I have not seen difluprednate emulsion cause IOP spikes of any greater amount or frequency than I have seen with prednisolone acetate or dexamethasone. Of course, I do not use difluprednate 0.05% emulsion where using loteprednol would be more appropriate (such as on the ocular surface).

I have found difluprednate particularly useful with highly inflammatory conditions such as uveitis and iridocyclitis. It also works extremely well in eyes that have had interstitial keratitis or stromal herpetic keratitis. In fact, I used this emulsion concomitantly with oral prednisolone acetate in a patient with scleritis, who responded very well.

I am now using difluprednate 0.05% emulsion in approximately 75% to 80% of my iritis cases (I still give prednisolone acetate to those concerned about cost) and in 10% to 20% of my total cases of ocular inflammation. This steroid has become my mainstay for addressing inflammation, as well as for iritis or significant stromal keratitis.

INSTRUCTIONS FOR CME CREDIT

1 AMA PRA Category 1 Credit™

Expires September 2011

CME credit is available electronically via www.dulaneyfoundation.org.

To answer these questions online and receive real-time results, please visit www.dulaneyfoundation.org and click "Online Courses." If you are experiencing problems with the online test, please e-mail us at support@dulaneyfoundation.org or call +1-610-619-0414. Alternatively, you may fax your exam to us at +1-610-771-4443. Certificates are issued electronically, so supply your e-mail address below. Please type or print clearly, or we will be unable to issue your certificate.

Name _____ MD participant non-MD participant

Phone (required) _____ E-mail (required) _____

City _____ State _____

1. Studies conducted in Japan estimated that the betamethasone molecule was how many times stronger than prednisolone acetate?⁶

- a. three times
- b. four times
- c. five times
- d. six times

2. What are some differences between emulsion and suspension formulations?

- a. emulsions do not require shaking to mix
- b. emulsions remain homogenous and particulates do not settle or separate
- c. emulsions provide a consistent dose of drug
- d. all of the above

3. Which dosing of difluprednate 0.05% emulsion was effective at treating refractory uveitis patients who had failed on betamethasone dosed 8 to 12 times per day?¹²

- a. b.i.d.
- b. q.i.d.

4. Phase 3 trials showed that difluprednate 0.05% emulsion was particularly effective dosed either b.i.d. or q.i.d. at decreasing inflammation and pain following ocular surgery in patients presenting with how many cells in the anterior chamber?¹⁸

- a. at least 6 cells
- b. at least 8 cells
- c. more than 10 cells
- d. more than 12 cells

5. What was the rate of clinically significant IOP rise (defined as greater than or equal to 21 mm Hg and greater than or equal to 10 mm Hg from baseline) for the difluprednate q.i.d. and b.i.d. groups in the postcataract studies?¹⁸

- a. 1.5%
- b. 2.8%
- c. 5.2%
- d. 7.1%

6. In the treatment of anterior uveitis, what was the dosing regimen for difluprednate 0.05% emulsion and prednisolone acetate?¹⁹

- a. b.i.d. for difluprednate 0.05% emulsion and eight times per day for prednisolone acetate
- b. q.i.d. for difluprednate 0.05% emulsion and eight times per day for prednisolone acetate
- c. b.i.d. for difluprednate 0.05% emulsion and q.i.d. for prednisolone acetate
- d. q.i.d. for both

7. What is difluprednate 0.05% emulsion preserved with?

- a. benzalkonium chloride
- b. sorbic acid

8. In the phase 4 study for the treatment of postoperative inflammation, at 1 month, which corticosteroid group had thinner retinas?²¹

- a. difluprednate 0.05% emulsion
- b. prednisolone acetate 1%
- c. there was no significant difference in retinal thickness between the two

ACTIVITY EVALUATION

Your responses to the questions below will help us evaluate this CME activity. They will provide us with evidence that improvements were made in patient care as a result of this activity as required by the Accreditation Council for Continuing Medical Education (ACCME). Please complete the following course evaluation and send it back to the Dulaney Foundation via fax at +1-610-771-4443.

Name and e-mail _____

Do you feel the program was educationally sound and commercially balanced? Yes No

Comments regarding commercial bias:

Rate your knowledge/skill level prior to participating in this course: 5 = High, 1 = Low _____

Rate your knowledge/skill level after participating in this course: 5 = High, 1 = Low _____

Would you recommend this program to a colleague? Yes No

Do you feel the information presented will change your patient care? Yes No

If yes, please specify. We will contact you by e-mail in 1 to 2 months to see if you have made this change.

If no, please identify the barriers to change.

Please list any additional topics you would like to have covered in future Dulaney Foundation CME activities or other suggestions or comments.

Advanced
OCULAR CARE